

CASE REPORT

A Simplified Technique to Create and Accurately Transfer an Optimal Emergence Profile Around Anterior Implant using Dynamic Compression Technique and Customized Transfer Coping

Sumit Makkar¹, Shivang Aggarwal², Surbhi Mehta³

ABSTRACT

Achieving soft tissue architecture is of paramount importance for success of implants in the esthetic zone. Soft tissue management around implant-supported restorations presents a challenge for the restoring dentist as well as the laboratory technician while fabricating the final prosthesis. This article describes a clinical method, in which conditioning of the soft tissue is carried out with the help of provisional restoration which applies pressure to contour the soft tissue. The aim is to establish an adequate emergence profile, recreate a balanced mucosa course and level in harmony with the gingiva of the adjacent teeth. This technique also serves to establish papilla height/width, localization of the mucosal zenith, and the tissue profile's triangular shape.

Keywords: Anterior implants, Aesthetics, Emergence profile

How to cite this article: Makkar S, Aggarwal S, Mehta S. A Simplified Technique to Create and Accurately Transfer an Optimal Emergence Profile Around Anterior Implant using Dynamic Compression Technique and Customized Transfer Coping. *Int J Oral Care Res* 2018;6(1):S100-103.

Source of support: Nil

Conflicts of interest: None

INTRODUCTION

The interface between fixed prostheses and soft tissues is important for the success of restorations in the anterior region.^[1] The emergence profile is defined as that portion of the tooth contour that extends from the base of the gingival sulcus past the free gingival margin to the height of contour facially and lingually and to the contact areas proximally.^[2] Management of soft tissue

especially in the esthetic zone is of paramount importance to create a soft tissue profile that resembles that of a natural tooth. The final prosthetic outcome can be compromised if the treatment plan does not include steps to preserve the patient's natural gingival contours and margins.^[3,4] To optimize the emergence profile and minimize the occurrence of black triangles, clinicians can follow an approach that leverages restorative-driven treatment planning, immediate extraction and implant placement, custom abutments, and crown design to achieve a predictable, and highly esthetic outcome.

The following case report describes a simplified technique to create and accurately transfer an optimal emergence profile.

CASE REPORT

A 21-year-old male patient reported to the Outpatient Department of Subharti Dental College, Meerut, with a chief complaint of missing right central incisor since past 1 year [Figure 1]. The patient was given various treatment options for replacement of the missing teeth. Implant placement was planned for replacement of the missing teeth.

A detailed medical and dental history of the patient were recorded.

Preoperatively diagnostic impressions were made and cone beam computed tomography analysis was done to identify the quality and quantity of bone. Implant of 3.75 mm × 11.5 mm (Alpha-Bio®-DFI, Israel) was planned at the proposed implant site. Implant placement was carried out using a standard two-stage procedure. A week after implant placement a bonded temporary acrylic restoration was given to the patient [Figure 2].

After 4 months 2nd stage surgery was carried out, and a stock abutment with 15° angulation was placed. After this, an abutment level impression was made. Over this, a temporary acrylic crown was fabricated. Starting from the round diameter of the implant, a soft tissue profile has to be created according to the planned reconstruction that mimicks and matches a natural tooth with gingiva and the adjacent dentition. Soft tissue

¹Reader, Private ²Practitioner, ³PG Student

^{1,3}Department of Prosthodontics and Crown and Bridge, Subharti Dental College, Meerut, Uttar Pradesh, India

²Department of Prosthodontics, Fusion Dental Care and Implant Centre, New Delhi, India

Corresponding Author: Dr. Shivang Aggarwal, Private Practitioner, Department of Prosthodontics, Fusion Dental Care and Implant Centre, 116, Hargobind Enclave, New Delhi – 110092, India. Phone: +91-8279459732. e-mail: drshivang.agg@gmail.com

management with the dynamic compression technique was performed by first inducing pressure to guide the soft tissue and squeeze it in the right position with the help of a provisional crown [Figure 3]. The initial reaction that occurred on the mucosa after insertion of the provisional prosthesis was ischemic type, causing blanching of the peri-implant soft tissue which disappeared within 15 min.^[5] This waiting is recommended to ensure the peripheral blood perfusion is re-established at the site. This reaction should be limited only halfway to the adjacent tooth. Selective pressure was applied by adding volume using flowable composite resin on selected sites. Material was added extraorally by first marking the site with a pencil. After each additive, the provisional was polished. This was continued until a desired soft tissue profile was achieved. It took a total of 45 days to achieve the desired results [Figure 4a and b]. The goal was to recreate a balanced mucosa/gingival level matching the adjacent dentition, to establish an accurate emergence profile, to relocate precisely the gingival zenith, to achieve balanced papilla height/width, and to create a proximal contact area with the adjacent tooth/implant crown.

Next step was to transfer this customized soft tissue profile on to the master cast. For this, an indirect

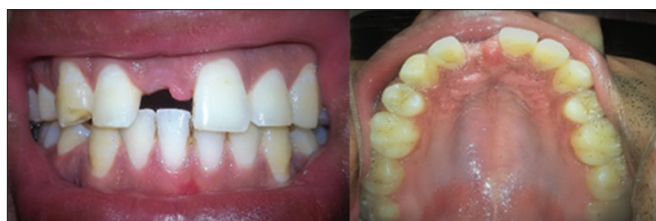

Figure 1: Missing central incisor

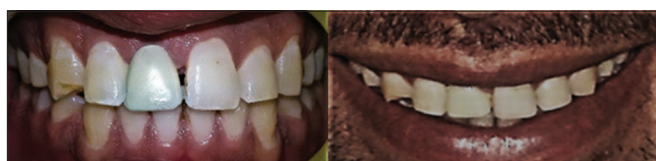


Figure 2: Bonded temporary acrylic restoration 1 week after implant placement

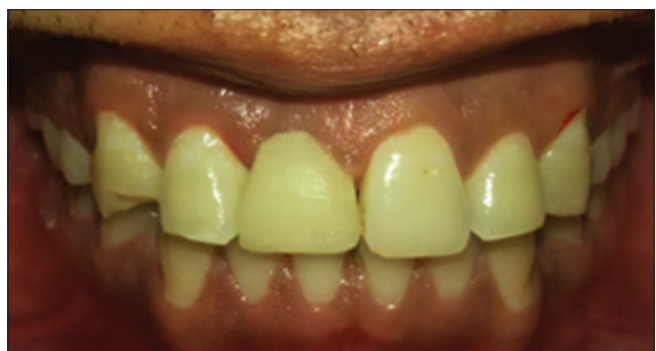

Figure 3: Dynamic compression technique to guide the soft tissue

technique was used. For this, the transfer coping was customized. Implant analog was mounted on Plaster of Paris [Figure 5] over which the abutment with the temporary crown was placed, and a putty index was made [Figure 6]. The transfer coping was customized with the help of a flowable composite. The customized transfer coping was removed and was finished and polished until no sharp points were left on the composite. Next, the transfer coping was placed in the patient mouth, and the composite was contoured until there was no blanching on the gingiva [Figure 7]. An open tray impression was made using Vinyl Polysiloxane Addition silicone-Putty and Light body (3M ESPE) [Figure 8].

A customized nickel free titanium milled abutment was fabricated by the laboratory [Figure 9]. Abutment trial was done in the patient [Figure 10], and the fit was confirmed with the help of intraoral periapical radiograph (IOPAR). Then, an all-ceramic restoration (Czar) was fabricated and finally cemented using glass-ionomer cement [Figure 11]. An IOPAR was taken to check for excess cement.

DISCUSSION

A natural, harmonious gingival morphology is an integral part of the esthetic tooth- and implant-supported prosthetic restorations. The pink esthetics (soft tissue) which form a natural frame for any restoration is as important as the final esthetic and functional restoration (white esthetics).^[6,7] Achieving a natural soft tissue contour is a challenge for the prosthodontist whenever soft and hard tissue defects are present. With standard transfer copings, it is difficult to transfer the final

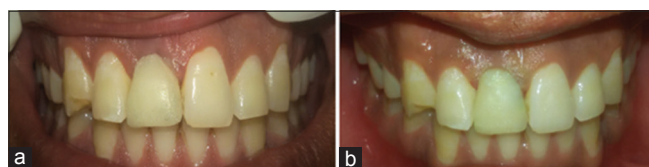

Figure 4: (a) Results after 20 days (b) results after 45 days




Figure 5: Mounted implant analog

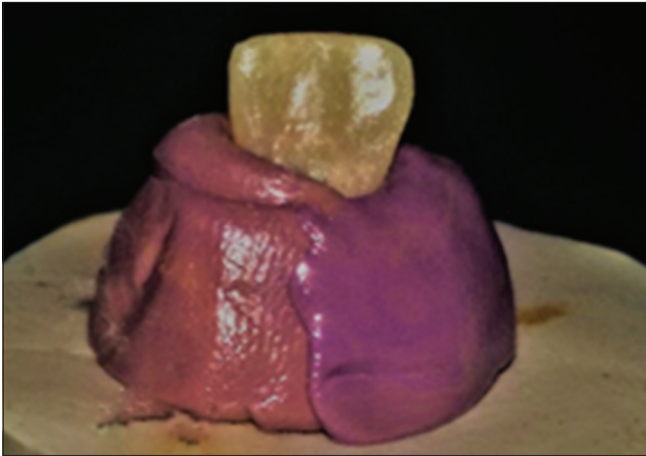


Figure 6: Putty index made




Figure 9: Customized abutment

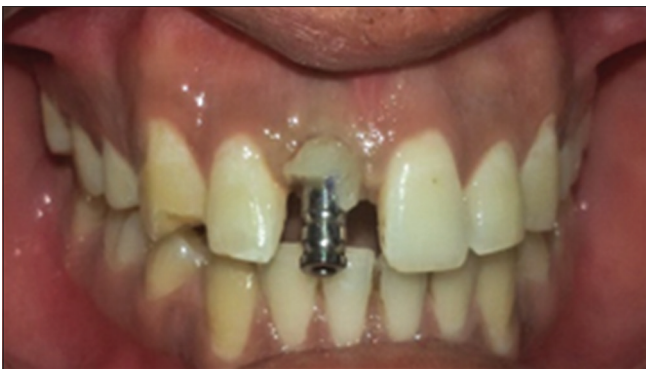

Figure 7: Customized transfer coping

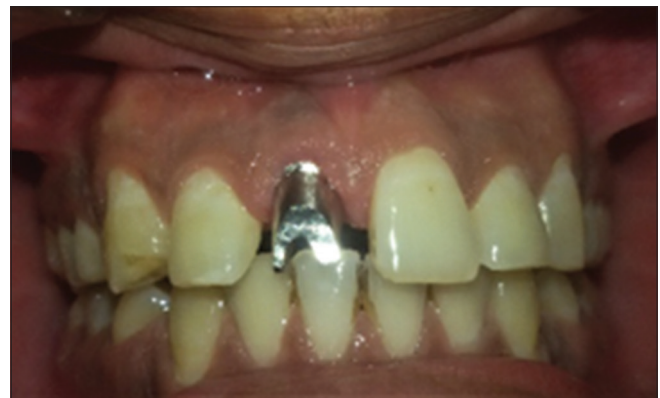

Figure 10: Fit checked inpatient

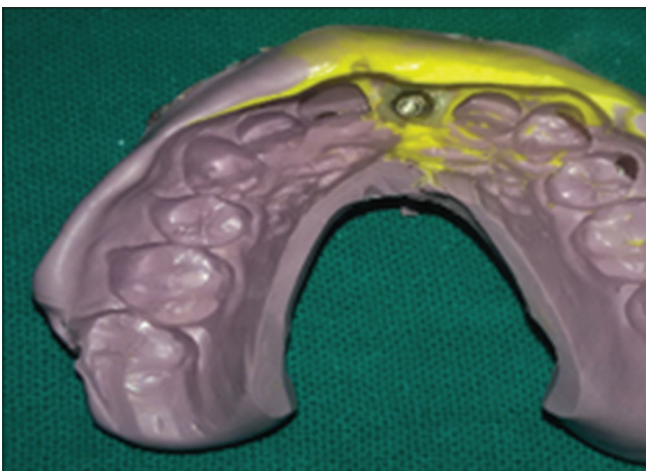


Figure 8: Final impression

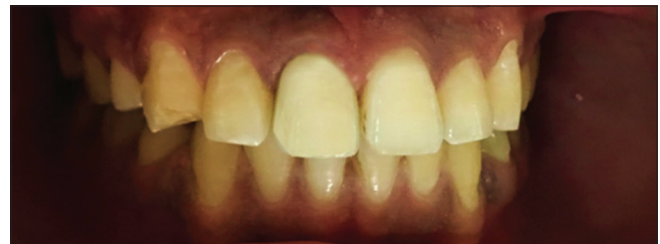

Figure 11: Final restoration with customized emergence profile

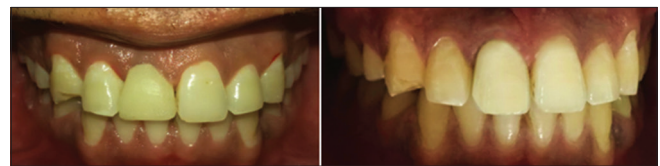


Figure 12: Difference in the emergence profile can be appreciated from the start of the restorative phase to the final restoration

shape to restoration even after creating an optimal emergence profile. This is due to the cylindrical geometry of standard impression copings which fails to transfer accurately the three-dimensional shape of the natural emergence profile of incisor teeth. Multiple techniques have been described to overcome these problems with customized impression copings.^[8]

This article has described technique for creating and accurately transferring of optimal emergence profile for anterior single-tooth implant restorations.

Initially, squeezing the tissue into the right direction is very important. Pressure with the provisional restoration pushes soft tissue laterally to direct it in the right way.^[8] Contouring the soft tissue with the help of provisional restoration appears to be a minimally invasive method with predictable esthetic outcomes. Its primary disadvantage is that it takes a longer time. Our clinical outcome, with a limit of one case report, showed that temporary crown along with accurate transfer of the soft tissue profile on the master cast can

be used to form the emergence profile of peri-implant soft tissue in harmony with the adjacent teeth, as well as to achieve proper height and width of interdental papilla [Figure 12]. Temporary crown also facilitates communication between the patient, dentist, and dental technician and provides predictable and extraordinary esthetic result with final restoration.

CONCLUSION

The provisional restoration plays an important role in determining the final architecture of the soft tissue in the esthetic zone. It helps to create a suitable emergence profile in the anterior region.

The technique described initially induces pressure at the selected site using a provisional restoration, and subsequently restoration is modified to achieve the desired results.

The long-term stability of the peri-implant soft tissue using this technique needs to be evaluated.

REFERENCES

1. LeSage BP. Improving implant aesthetics: Prosthetically generated papilla through tissue modeling with composite. *Pract Proced Aesthet Dent* 2006;18:257-63.
2. Croll BM. Emergence profiles in natural tooth contour. Part I: Photographic observations. *J Prosthet Dent* 1989;62:4-10.
3. Perel ML. Periodontal considerations of crown contours. *J Prosthet Dent* 1971;26:627-30.
4. Perel ML. Axial crown contours. *J Prosthet Dent* 1971;25:642-9.
5. Cooper LF. Objective criteria: Guiding and evaluating dental implant esthetics. *J Esthet Restor Dent* 2008;20:195-205.
6. Chen ST, Buser D. Clinical and esthetic outcomes of implants placed in postextraction sites. *Int J Oral Maxillofac Implants* 2009;24 Suppl:186-217.
7. Elian N, Tabourian G, Jalbout ZN, Classi A, Cho SC, Froum S, *et al.* Accurate transfer of peri-implant soft tissue emergence profile from the provisional crown to the final prosthesis using an emergence profile cast. *J Esthet Restor Dent* 2007;19:306-14.
8. Wittneben JG, Buser D, Belser UC, Brägger U. Peri-implant soft tissue conditioning with provisional restorations in the esthetic zone: The dynamic compression technique. *Int J Periodontics Restorative Dent* 2013;33:447-55.